

Intractable Seizures and Metabolic Bone Disease Secondary to Celiac Disease

Vashishth P Maniar*, Sameer S Yadav**, Yojana A Gokhale***

Abstract

Celiac disease (CD) is Gluten sensitive enteropathy with a wide spectrum of severity and protean clinical manifestations. Patients with atypical (non-diarrhoeal) presentations are missed as the diagnosis of Celiac Disease is not considered. We present three young girls (ages 18, 19, 23 at presentation) who were admitted to our hospital as intractable seizures. All had low serum calcium, features of rickets/ osteomalacia and anaemia. This prompted us to consider malabsorption due to CD. The diagnosis of CD was confirmed by serologic tests (IgA transglutaminase and IgG antigliadin antibodies) and biopsy of the duodenum.

In all patients gluten free diet not only provided drug free control of seizures but also helped correct other features of malabsorption like hypocalcaemia and anaemia as the primary pathology behind these symptoms was corrected. We wish to highlight that hypocalcaemia of CD which may present as intractable seizures can be treated only by treating CD with gluten free diet and not by oral vitamin D and Calcium alone.

Introduction

Celiac disease (Nontropical sprue, gluten-sensitive enteropathy) is a unique auto-immune disease (unique because environmental precipitant is known) of the small intestine induced by ingestion of gluten (such as wheat, rye, barley) in genetically susceptible individuals.¹ It has an estimated prevalence of 1% with females being twice more commonly affected worldwide. In Indian school children its prevalence was found to be 1 in three hundred ten.² The symptoms of CD may appear with introduction of cereals in an infant's diet or may first become evident only in adulthood after surgery, pregnancy, viral infection or emotional stress. The classic or typical signs of Celiac disease are related to the gastrointestinal tract and form only the proverbial tip of an iceberg presenting

with diarrhoea, abdominal pain, bloating, foul smelling stools. Extra intestinal manifestations (atypical) include dermatitis herpetiformis, arthralgia, alopecia, anaemia, coagulopathy, metabolic bone diseases, infertility, psychiatric syndromes and various neurological disorders. Also known are Latent and silent disease variants. The last two are asymptomatic, only serology being positive. In latent, biopsy is abnormal but in silent, Biopsy is Normal. CD is an under diagnosed disease. Neurological symptoms can be the presenting feature in as high as 6-10% of newly diagnosed cases of CD.³ An association prevails between celiac disease and epilepsy however; the previously described syndrome of CD, epilepsy, and intracranial occipital calcifications seems to be rare in adults. Gluten free diet restores the mucosal function and prevents the development of various systemic complications of untreated celiac disease.

Table 1 : Clinical features

	Case no. 1	Case no. 2	Case no. 3
Sex / yr of presentation	F/19 y in 2002	F/18 y in 2007	F/ 23y in 2009
Age of 1 st seizure	13 yrs	11 yrs	22 years
No. of Seizure	1-2/month	1-2/week	2/month
No. Of anti-epileptics	Phenytoin/ carbamazepine	Phenytoin/ valproate/ phenobarbitone	Phenytoin/ valproate
Seizure control	Poor	Poor	Poor
GI symptoms	Absent	2-3 loose stools since 10 months	Absent
Other features	Traumatic hemarthrosis following seizure on 2 occasions	Unable to get up from squatting position since 6 months (osteomalacic myopathy, waddling gait)	Unable to get up from squatting position since 1 month (trivial trauma fractures of both pubic rami)
On General examination	Genu Valgum	Pallor, genu Valgum, B/L cervical LN.	Pallor

Table 2 : Laboratory profile

	Case 1	Case 2	Case 3
Hb with indices	11gm% MCV-56fl MCH-21fl MCHC-26%	8.3gm% MCV-41fl MCH-19fl MCHC-22%	8.9gms% MCV-60fl MCH-24fl MCHC-22%
T. PROT/ALB	4.6gm/dl 2.7 gm/dl	4.5 gm/dl 2.2 gm/dl	5.3 gms/dl 2.8 gms/dl
Sr. Ca/Po4	6.6mg/dl 2.2 mg/dl	4.8mg/dl 2.4 mg/dl	5.1mg/dl 2.9 mg/dl
Sr. Alk Phos	610 IU/dl	715IU/dl	599 IU/L
Sr. PTH	110pg/ml	172pg/ml	108pg/ml
Sr. Vit D3	6.3 nanogm	5.6 nanogm	4.8 nanogm
Stool R/M	NAD	NAD	NAD
CT Brain	NORMAL	NORMAL	NORMAL
XRAYs	PBH*- Generalised Osteopenia	Rt upper zone TB. PBH*- revealed osteopenia with looser's zone	PBH*- fracture of bilateral pubic rami
EEG	Normal	Frontal activity	Normal
Sr. IgG Anti-Gliadin abody	120u/ml (N<11 u/ml)	84u/ml	106u/ml
Sr. IgA anti Tissue Transglutaminase	<10IU Normal<10 IU	12 IU	17 IU
Duodenal biopsy	Subtotal villous atrophy consistent with coeliac disease	Absent duodenal folds with flattening of villi.	Villous atrophy

*Resident, **Lecturer, ***Professor, Department of Medicine, Lokmanya Tilak Municipal Medical college and General Hospital, Sion, Mumbai
Received: 05.06.2009; Revised: 25.11.2009; Accepted: 27.11.2009

Table 3 : Treatment and follow up

	Case 1	Case 2	Case 3
Gluten free diet started	Yes	Yes, along with ATT	Yes
Response to Gluten free diet	weight gain- 18 kgs over 2 yrs, seizure free off anti-epileptics.	Weight gain and gained 4 cms in height in 8 months seizure free off anti-epileptics	Seizure free since 6 months till last follow up.

Cases

We present 3 patients who were referred to our institute as cases of intractable seizures with poor control on multiple anti-epileptics and only 1 of these 3 on direct inquiry gave history of loose motions. Presence of hypocalcaemia, anaemia and musculoskeletal abnormalities suggestive of childhood rickets or osteomalacia prompted us to investigate them for celiac disease, which was proven by serology and duodenal biopsy changes (Fig. 1). All of these patients showed drastic response to gluten free diet in the form of general well being, weight gain and most importantly drug free seizure control. Their clinical features and laboratory profiles are depicted in tables 1 and 2.

Discussion

It was a Dutch paediatrician, W.K. Dicke (1950), who first reported a significant decrease in prevalence of paediatric diarrhoeas in the post world war countries. He attributed it to the decrease in bread (wheat) consumption in these countries due to scarcity of bread. He was the first to correlate the harmful effect of ingested wheat gluten with diarrhoea. A few years later Pauley (1954) reported small bowel mucosal villous atrophy with chronic inflammation as a constant finding in this condition. The development of per oral intestinal biopsy in 1957 made diagnosis of celiac disease possible. The 1970 criteria required three duodenal biopsies for a confirmed diagnosis of celiac disease; it included first biopsy with histopathology consistent with celiac disease, second biopsy on institution of gluten free diet which showed resolution of histopathology changes, and third biopsy which showed reappearance of those changes on gluten challenge. With advent of highly sensitive and specific serological tests and revised ESPGN (European Society of Paediatric Gastroenterology, Hepatology and Nutrition revised CD diagnostic protocol) criteria, diagnosis became easier. The ESPGN criteria mentions that in a given clinical setting, one serological test, a biopsy consistent with the diagnosis of CD (characteristic histopathological changes being villous atrophy, crypt hyperplasia and increased inflammatory cell infiltrates seen on distal duodenum), and reversal of symptoms on omission of gluten from diet, with absence of other causes of diarrhoea like milk intolerance are sufficient for the diagnosis of CD. The patho-physiology of CD involves interplay between the following factors;

1. Diet like wheat, rye, barley, which activate the disease
2. Genetic, in the form of strong association with specific alleles and
3. Immunological, being HLA-DQ2, HLA-DQ8 molecules which are bound to gluten peptide, trigger an inflammatory T cell response in the small intestine. Ninety five percentage of CD patients express HLA-DQ. The spectrum of CD has changed over the years with overt symptoms being rare.⁴ The neurological disorders described with CD are cerebellar ataxia, peripheral neuropathy, myelopathy, encephalopathy,

movement disorder, dementia, and epilepsy with or without intracerebral calcifications.⁵ Neurological complications are estimated to occur in 6 to 10% of patients with CD.³ Recently, a high proportion of patients with neurological symptoms of unknown origin were found to have gluten sensitivity.⁶ A definite association between CD and epilepsy has been recognised since the 1970's,⁷ which described the classical CEC syndrome comprising of CD, Epilepsy, and cerebral calcification (most commonly posterior occipital). An incomplete form (without epilepsy) has also been described. Occasionally development of calcification may

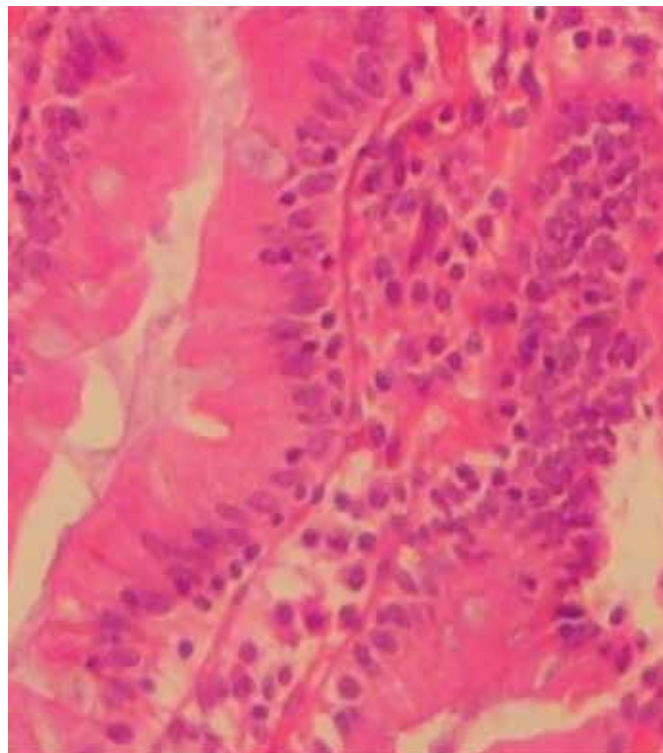


Fig. 1 : Microscopic view of Duodenal biopsy showing villous atrophy and intra-epithelial lymphocytic infiltrate.

succeed the development of celiac disease and epilepsy by many years.⁸

Recent studies indicate that presence of calcification is neither mandatory nor common in the diagnosis of CD. White matter lesions are now recognised as one of the common CNS lesions caused by gluten. Neurological symptoms may often precede or occur in the absence of gastrointestinal symptoms.⁹ Success of therapy depends on early diagnosis, as early institution of GFD is associated with better reversal of mucosal injury and improvement in symptoms. However, institution of gluten free diet may not always reverse the symptoms.¹⁰ Our experience has been novel in the form of all patients responding exceedingly well to gluten free diet. Seizures in CD may be difficult to control in view of poor absorption of anti epileptic drugs¹⁰ or delayed diagnosis of celiac disease. In patients suspected to have IgA deficiency it is always prudent to test for IgG anti gliadin antibody. Antigliadin antibodies have been found in the cerebrospinal fluid in patients with gluten sensitivity and neurological dysfunction.¹¹ Nevertheless these antibodies are present in almost all patient with CD, but only a small proportion of them develop neurological symptoms. One hypothesis maybe that antigliadin antibody becomes neurotoxic only if they gain access to the central nervous system.¹² Commonly recognised causes of poor treatment response include traces of gluten in



Fig. 2 : Patient of celiac disease presenting with genu valgum.

the diet and delayed diagnosis.

Metabolic bone disease associated with CD is due to malabsorption of vitamin D and calcium with resultant secondary hyperparathyroidism. It presents with features of vague aches and pains and myopathy. Investigations reveal low or low normal serum calcium, phosphorus, vitamin D levels, with increased or normal Sr. Alkaline phosphate levels. We have reported CD in osteoporotic Indians in our previous study.¹³ All three patients in our study had osteomalacic myopathy, with two of them having genu valgum (Figs. 2, 3) and one patient having fracture of pubic rami. All three had features of malabsorption in the form of microcytic hypochromic anaemia, hypoproteinaemia, hypocalcaemia however only one of them had classical symptom of diarrhoea.

Management of these patients necessitates life long gluten free diet to revert intestinal pathology and not mere oral supplements of Vit. D and Calcium.

Conclusion

Celiac disease, in the absence of typical symptoms is often an under diagnosed entity. In selected patients, presenting with intractable epilepsy, diagnosis of Celiac Disease should be considered even in the absence of GI symptoms. Gluten free diet if constituted early can be effective in reversing neurological symptoms. Presence of iron deficiency anaemia and features of metabolic bone disease along with intractable seizures make the diagnosis of celiac disease likely. Iron deficiency anaemia and metabolic bone disease respond to gluten free diet rather than just calcium and vitamin D supplementation. Diagnosis of celiac disease is often challenging and a clinician should be vigilant of the same due to its varied extraintestinal manifestations.

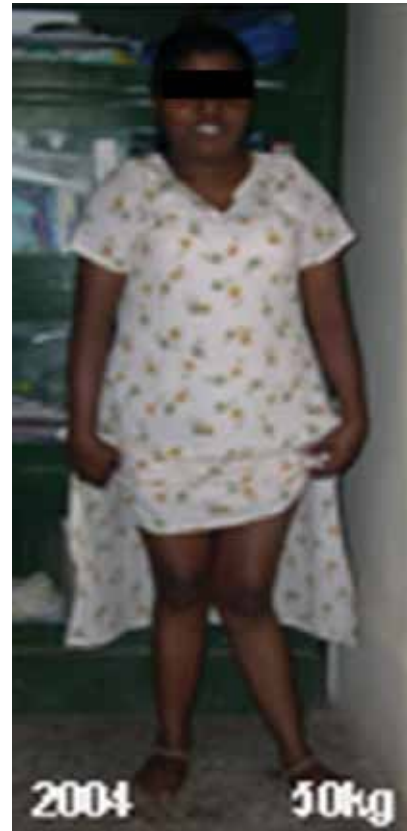

Fig. 3 : Same Patient on gluten free diet with significant weight gain.

References

1. Peter H.R. Green, M.D., and Christophe Cellier, M.D., Ph.D. Celiac Disease, *New England Journal of Medicine* 2007;357:1731-1743.
2. Ajit Sood; Vandana Midha; Neena Sood et al: prevalence: of celiac disease among school children in Punjab, North India. *Journal of Gastroenterology and Hepatology* 2006;21:1622-1625.
3. Lagerqvist C, Ivarsson A, Juto P. Screening for adult celiac disease – which serological markers to use? *J Intern Med* 2001;250:241-248.
4. Colin P, Julkenen R, Lehtola J. Celiac disease, treatment guidelines. *Duodecim* 1997;113:82-87.
5. Chin RL, Sander HW, Brannagan TH, et al. Celiac neuropathy. *Neurology* 2003;60:1581-1585.
6. Walker Smith JA, Guandalini S, Schmitz J et al. Revised criteria for diagnosis of Celiac Disease. *Arch Dis Child* 1990;65:909-911.
7. Chapman, R. W. G., Laidlow, J. M., Colin-Jones, D, et al. Increased prevalence of epilepsy in disease. *British Medical Journal* 1978;2:250-251.
8. Ambrosetto G, Antonini L, Tassinari CA. occipital lobe seizures related to clinically asymptomatic celiac disease in adulthood. *Epilepsia* 1992;33:476-81.
9. Hagen EM, Gjerde IO, Vedeler C, Hovdenak N. Neurological disorders associated with coeliac disease. *Tidsskr Nor Lægeforen* 2000;120:439-442.
10. Gobbi G, Bouquet F, Greco L, et al. Celiac disease, epilepsy and cerebral calcifications. *Lancet* 1992;340:439-443.
11. Chinnery PF, Reading PJ, Milne D, et al. CSF antigliadin antibodies and the Ramsay Hunt syndrome. *Neurology* 1997;49:1131-1133.
12. Hadjivassiliou M, Boscolo S, Davies-Jones GAB, et al. The humoral response in the pathogenesis of gluten ataxia. *Neurology* 2002;58:1221-1226.
13. Gokhale YA, Sawant PD, Chodankar CM, et al. Celiac disease in osteoporotic Indians. *J Assoc Physicians India* 2003;51:579-584.