

Sister Mary Joseph Nodule

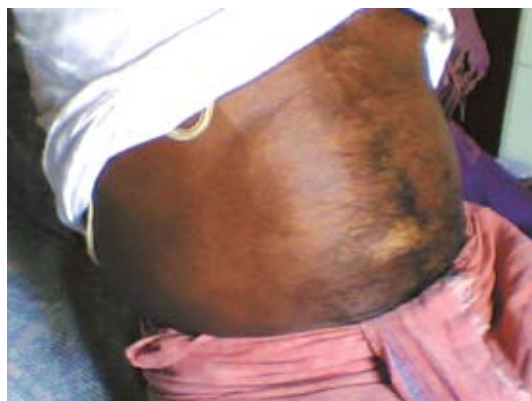

Fig. 1 : Patients with abdominal swelling

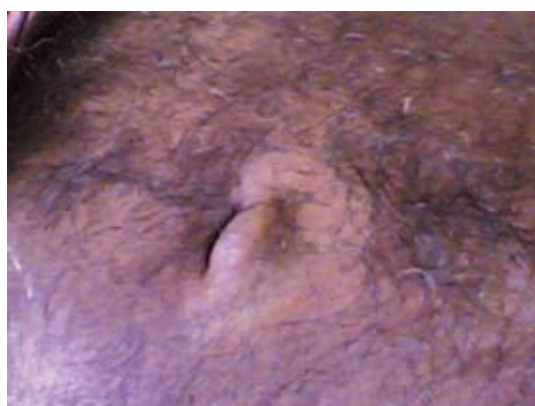

Fig. 2 : Sister Joseph Nodule

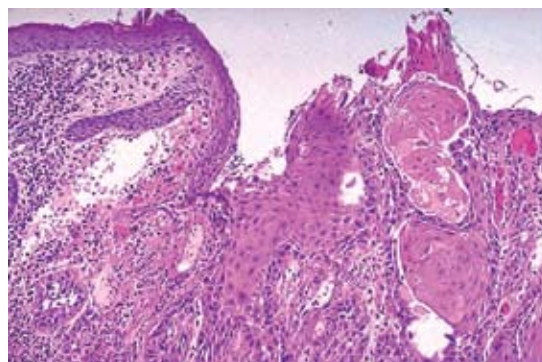


Fig. 3 : FNAC of nodule showing adenocarcinoma

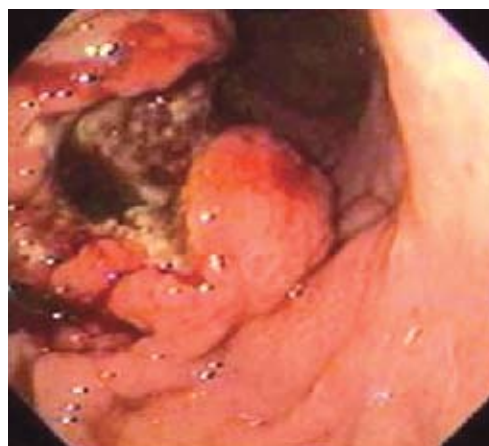

Fig. 4 : Upper GI endoscopy showing adenocarcinoma

A 67yr male admitted with dyspepsia, pain abdomen, black stool since 1 month. There was no history of fever, Hematemesis and altered bowel habit. Physical examination revealed emaciation, pallor and icterus. Examination of abdomen showed distended abdomen with a large periumbilical firm, indurated nodule of size 3 cm diameter which is irregular and painless without any ulceration or discharge. There was hepatomegaly which was firm non tender irregular & there was no splenomegaly and ascites. Other systemic examination was non contributory.

On investigation hemogram & biochemical examination were normal except for Hb = 8.4gm%, LFT (SGOT: 211.8 U/L, SGPT: 115 U/L, Bilirubin (T) – 4.6 mg/dl, serum protein: 6gm%, ALP: 590 U/L). Ultrasonography of abdomen showed large hepatomegaly with multiple echogenic secondary metastatic lesions. FNAC of the umbilical nodule showed metastatic adenocarcinoma (Sister Joseph's nodule). Upper GI endoscopy revealed adenocarcinoma of stomach in the lesser curvature. Patient was subjected to palliative treatment.

Sister Joseph's nodule is a time honored clinical sign with a rich history that often indicates advanced metastatic intraabdominal cancer like stomach, ovary, colon and pancreas due to its connection with multiple embryological remnants and extensive vascular and lymphatic communications. When found on physical examination, this nodule may provide physician with both a site on which a biopsy can be easily performed and a crude indicator of prognosis. Although advanced technology now exists to more easily diagnose malignancies, Sister Joseph's nodule nevertheless remains an interesting and useful diagnostic tool in modern medicine.

SC Mohapatra, N Mohanty, SS Acharya, RR Mohanty

PG Department of General Medicine, MKCG Medical College, Berhampur, Orissa**

Received : 14.1.2008; Accepted : 4.2.2008

REFERENCE

1. Urbano FL. Sister Joseph Nodule. Hospital Physician 2001; (vol-33-35).