

Does Hypertension Play a Role in Diabetic Retinopathy?

BK Srivastava, M Rema

Abstract

Diabetic retinopathy is a common complication of diabetes. It represents one of the frequent causes of visual disability among diabetic subjects during the period of active life. The risk factors for diabetic retinopathy are poor glycemic control, hypertension, duration of diabetes, hyperlipidemia and proteinuria.

It has been observed that prevalence of hypertension is higher in diabetic subjects than in the general population and as it also plays a major role in the progression of diabetic retinopathy, so tight control of hypertension is mandatory.

The possible mechanisms by which hypertension affects diabetic retinopathy are haemodynamic (impaired autoregulation and hyperperfusion) and secondly through VEGF (Vascular Endothelial Growth Factor), as it has been observed that hypertension independent of hyperglycaemia upregulates the VEGF expression in retinal endothelial cells and ocular fluids.

The level of control of blood pressure are debatable but nearer the blood pressure to the normal levels, better the chances of preventing the onset and progression of diabetic retinopathy. The lowering of blood pressure to a normal range is more important than the type of antihypertensive medication used.

Diabetic retinopathy is one of the important causes of visual disability in diabetic subjects during the period of active life. It is characterized by gradually progressive alterations in the retinal microvasculature, leading to increased vasopermeability, areas of retinal occlusion and retinal neovascularization. The complications associated with increased vasopermeability and uncontrolled neovascularization can result in severe and permanent visual loss.¹ ©

PREVALENCE OF DIABETIC RETINOPATHY

Diabetic retinopathy affects both Type 1 and Type 2 diabetic subjects. Our clinic based study in Type 2 diabetes mellitus patients had shown that 34.1% diabetic subjects had evidence of retinopathy, this included 30.8% with non-proliferative diabetic retinopathy (NPDR) and 3.4% with proliferative diabetic retinopathy (PDR).² Approximately, 25% of Type 1 patients have retinopathy after 5 years, increasing to 60 and 80% after 10 and 15 years respectively. Proliferative diabetic retinopathy (PDR), a sight threatening form of diabetic retinopathy is present in 25% of Type 1 diabetic patients after 15 years duration as shown in earlier studies.³ In the epidemiological study done at Chennai, the Chennai Urban Population Study (CUPS), the overall prevalence of diabetic retinopathy in Type 2 diabetic subjects was 19%, which included 17.5% with non-proliferative

diabetic retinopathy and 1.5% with proliferative diabetic retinopathy.⁴

Diabetic retinopathy can be present at the time of diagnosis of Type 2 diabetes mellitus due to insidious onset of the disease as shown in the United Kingdom Prospective Diabetes Study (UKPDS), which revealed that 39% of the men and 35% of women were having retinopathy at the time of diagnosis of diabetes.⁵ In our study, using colour photography for documentation of DR, only 7% of Type 2 diabetic patients had diabetic retinopathy at the time of diagnosis of diabetes.⁶ A distinctly lower prevalence rate of diabetic retinopathy is seen among south Indians as compared to the western population.

Classification and Clinical Features

Diabetic retinopathy is broadly classified into two groups, non-proliferative diabetic retinopathy (NPDR) and proliferative diabetic retinopathy (PDR). The clinical features of non-proliferative diabetic retinopathy are (a) microaneurysm (b) blot or dot haemorrhage (c) venous abnormalities (d) hard exudates, cotton wool spots and (f) intraretinal microvascular abnormalities (IRMA).

MV Diabetes Specialities Centre and Madras Diabetes Research Foundation, 6, Conran Smith Road, Gopalapuram, Chennai 600 086.

Received : 5.10.2004; Accepted : 4.7.2005

Proliferative diabetic retinopathy is characterized by neovascularization on surface of retina or optic disc and/or vitreous/preretinal haemorrhage.⁷⁻⁹

On the basis of consensus disease severity scale graded by ophthalmoscopy by Wilkinson *et al*, diabetic retinopathy has been further classified from no apparent retinopathy level to mild, moderate and severe NPDR and PDR. Diabetic Macular Edema (DME) has been classified in apparently absent diabetic macular edema and apparently present diabetic macular edema, which has been again subdivided into mild, moderate and severe depending on the proximity of DME to the fovea.⁹

Association of Hypertension With Diabetic Retinopathy

Diabetes, hypertension and cardiovascular disease are the common non-communicable diseases. India leads the world with 30 million diabetic subjects currently. In our study, Chennai Urban Population Study (CUPS), the overall prevalence of hypertension in the non-diabetic population was 16.7%, while diabetic subjects had a 3 times higher prevalence of hypertension i.e. 46.7%.¹⁰ In the Wisconsin Epidemiologic Study of Diabetic Retinopathy (WESDR) in patients with type 1 diabetes, the prevalence of hypertension at baseline was 17.3% and the 10 year incidence was 25.9%. In the UKPDS 38% of the newly diagnosed patients with Type 2 diabetes had hypertension and in the years after diagnosis of type 2 diabetes, the prevalence of hypertension was higher than in the age matched general population.¹¹

Several studies have shown an association between hypertension and the presence and severity of retinopathy in subjects with diabetes. The UKPDS have shown a significant association of systolic blood pressure with diabetic retinopathy in Type 2 diabetic subjects. Diabetic subjects with a systolic blood pressure ≥ 140 mmHg were 2.8 times more likely to develop retinopathy as compared to diabetic subjects with systolic blood pressure < 125 mmHg. In the WESDR in Type 1 diabetic patients, diastolic blood pressure was a significant predictor of progression of diabetic retinopathy, independent of glycosylated haemoglobin (HbA_{1c}) and the presence of gross proteinuria.^{12,13}

PATHOPHYSIOLOGY OF PROGRESSION OF DIABETIC RETINOPATHY DUE TO HYPERTENSION

Though a lot of studies have shown the association between hypertension and diabetic retinopathy, the exact pathogenesis is not known. However, the available evidence supports the theory that a) haemodynamic alterations in retinal microvasculature and b) hypertension induced increased expression of VEGF (Vascular Endothelial Growth Factor) could be the probable mechanisms involved in the progression of diabetic retinopathy.

A. Haemodynamic alterations in retinal microvasculature

Increased retinal blood flow may be of importance in the pathogenesis of diabetic retinopathy. It has been observed that conditions associated with increased blood flow like pregnancy, autonomic neuropathy, hyperglycemia and hypertension are associated with progression of diabetic retinopathy. However conditions such as raised intraocular pressure, good diabetic control and moderate stenosis of the carotid artery, which reduces or normalizes retinal blood flow, have a protective effect. Blood flow distribution is controlled by central and local mechanisms. The central mechanism is by autonomic innervation, while local mechanism is through autoregulation. Autoregulation is the ability of the vessels to keep blood flow constant in the face of change in perfusion pressure.¹⁴

The special importance of autoregulation in the retina lies in the fact that while the ophthalmic artery has rich autonomic innervation, the retinal vessels do not, and hence the control of blood flow through the retina is by autoregulation. Studies by Kohner *et al* have demonstrated that in non-diabetic subjects the retinal blood flow did not change significantly until mean arterial pressure (MAP) rose by 40%. In well-controlled diabetic patients, there was 20% increase in blood flow at a 30% increase in mean arterial pressure. In the same patient, when blood glucose was 270 mg/dl, blood flow was already increased by $> 25\%$ when the MAP rose 15% above baseline and was increased by $> 100\%$ when the pressure was raised by 40%. This suggests the link between retinal haemodynamic changes, hyperglycemia and hypertension. It has also been observed that not only does the retinal blood flow increase but choroidal blood flow is also elevated in the early stages of diabetic retinopathy.¹⁴⁻¹⁶

The impaired autoregulation in diabetic patients may be due to reduced contractile capability of retinal pericytes (as shown by resistance to endothelin-1 in retinal microvessels)¹⁷ or capillary basement thickening as well as arteriolar hyaline sclerosis limiting the capacity of microvasculature to autoregulate.¹⁸ Inability to autoregulate makes the retinal microvascular bed pressure passive, so that any increase or decrease in arterial blood pressure will be transmitted to the retinal microvasculature. Besides this, increased blood pressure also increases retinal blood flow. Fig. 1 shows the probable mechanism by which haemodynamic alterations in retinal microvasculature can lead to irreversible structural changes leading to worsening of diabetic retinopathy.¹⁹⁻²¹

B. Role of VEGF

The eye contains highly vascularised and completely avascular tissue in close apposition. This specialised anatomy requires tight balance between vascular quiescence and vascular growth. This delicate balance

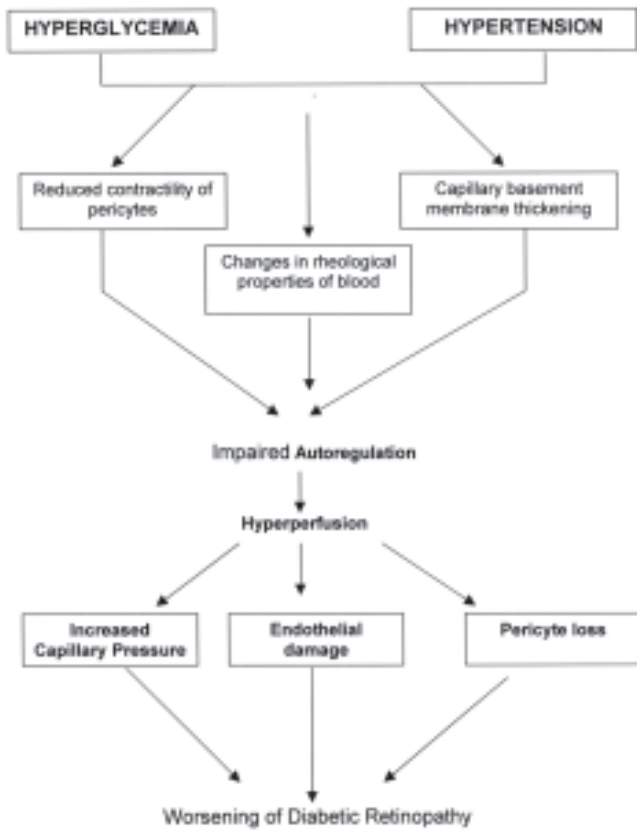


Fig. 1 : Haemodynamic alterations in retinal microvasculature leading to worsening of diabetic retinopathy.

gets disturbed in eye diseases associated with angiogenesis like diabetic retinopathy. A biochemical factor capable of inducing vascular ingrowth is vascular endothelial growth factor (VEGF), which is a glycoprotein dimer of 34-45 KDa. Four different isoforms of VEGF (with 206, 189, 165 and 121 amino acids) arise from the same gene by alternative splicing. Two high affinity receptors for VEGF, namely VEGF R-1 or Flt-1 and VEGF R-2 or KDR have been characterized, which are transmembraneous proteins with cytoplasmic tyrosine kinase domains and are expressed on endothelial cells including retinal endothelial cells. KDR is involved primarily in mitogenesis, mediating most of the VEGF's endothelial cell selective growth and permeability actions.²²

VEGF - mRNA upregulation and significantly elevated levels of VEGF has been seen in ocular fluids from patients with PDR as compared to patients without diabetic retinopathy. Upregulation of VEGF-KDR mRNA has been seen in hypertensive patients. This is mainly due to increased cyclic stretch of retinal microvessels leading to increased intracellular signalling of certain unknown pathways, resulting in its upregulation. Besides this, an increase in angiotensin-II (which is increased due to increased activity of Renin Angiotensin system in hypertensives) binding to AT-I receptor also upregulates the VEGF-KDR mRNA. All these events lead

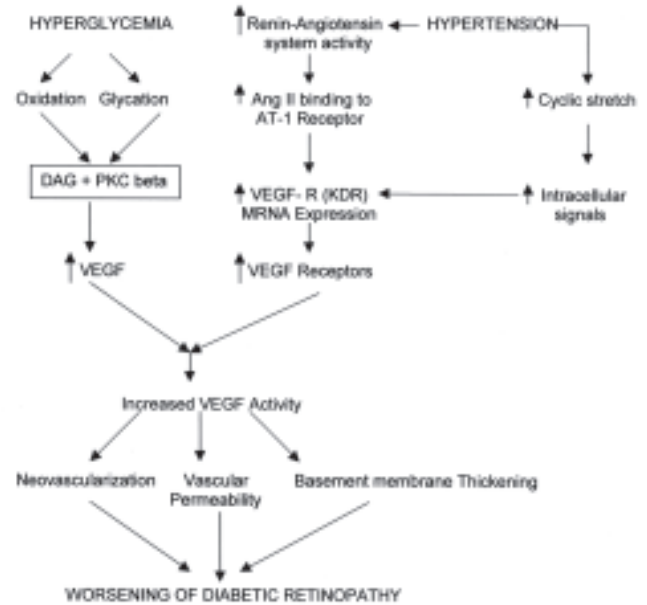


Fig. 2 : Illustration of hypertension worsening diabetic retinopathy by increasing VEGF-activity.

to increased VEGF expression. Increased VEGF levels in presence of increased VEGF receptor expression can lead to basement membrane thickening, increased vascular permeability and neovascularization as shown in Fig. 2.²³⁻²⁶

Other systemic factors affecting diabetic retinopathy

As diabetes mellitus is a metabolic disorder affecting various systems, optimal ophthalmic care must include diligent evaluation and treatment of concomitant systemic disorders that influence the development, progression and ultimate outcome of diabetic retinopathy. Apart from hypertension the other systemic factors affecting diabetic retinopathy are hyperglycemia, nephropathy, hyperlipidemia and anaemia. Besides these factors, certain situations like pregnancy, unaccustomed exercise, smoking and treatment with anticoagulants have also been reported to have deleterious effects on diabetic retinopathy.²⁷⁻³⁴

Benefits of control of hypertension

A causal relationship between diabetic retinopathy and hypertension is strongly suggested from the results of UKPDS in Type 2 diabetic subjects who were randomized to a tight BP control group (758 patients) and to a less tight control groups (390 patients) with median follow-up of 8.4 years. Significant BP reduction was achieved in the tight control group (mean BP of 144/82 mmHg) compared with the group assigned to less tight control (mean BP of 154/87 mmHg). In the group assigned to tight BP control, there was a 34% reduction in risk in the proportion of patients with deterioration of retinopathy by two steps and a reduced risk of deterioration in visual acuity by three lines of the ETDRS chart.³⁵

Table 1 : Diabetic retinopathy disease severity scale⁹

Proposed disease severity level	Findings observable on dilated ophthalmoscopy
No apparent retinopathy	No abnormalities
Mild non-proliferative diabetic retinopathy	Microaneurysms only
Moderate nonproliferative diabetic retinopathy	More than just microaneurysms but less than severe nonproliferative diabetic retinopathy
Severe nonproliferative diabetic retinopathy	Any of the following : more than 20 intraretinal haemorrhage in each of 4 quadrants; definite venous beading in 2+ quadrants; Prominent intraretinal microvascular abnormalities in 1+ quadrant. No signs of proliferative retinopathy
Proliferative diabetic retinopathy	One or more of the following neovascularization, vitreous preretinal haemorrhage

The above results are inconsistent with the Appropriate Blood Pressure Control in Diabetes (ABCD) Trial, a prospective randomized blinded clinical trial, comparing the effects of intensive (diastolic blood pressure goal of 75 mmHg) and moderate (diastolic blood pressure goal of 80-89 mmHg) blood pressure control on diabetic retinopathy in hypertensive Type 2 diabetic subjects, who were followed for 5 years. The mean BP achieved in intensive group was 132/78 mmHg compared to 138/86 mmHg in moderate group. There was no difference between the groups with regard to retinopathy progression. The authors concluded that lack of efficacy in their study compared to the UKPDS might have resulted from the shorter time period of the ABCD trial (5 years versus 9 years on average for the UKPDS), lower average blood pressure control in ABCD trial (132/78 mmHg v/s 138/86 mmHg in ABCD trial in comparison to 144/82 mmHg v/s 154/87 mmHg in the UKPDS) and poorer glycemic control in ABCD trial than the UKPDS.^{36,37}

Levels of control

The benefits of blood pressure control have been elegantly demonstrated but the levels of control vary from study to study. The Hypertension Optimal Treatment (HOT) study demonstrate the benefits of lowering blood pressure in patients with hypertension to 140 mmHg systolic and 85 mmHg diastolic or lower. Although the efforts to lower blood pressure below 120 mmHg systolic and 70 mmHg diastolic appears to give little further benefit, it is particularly beneficial to lower blood pressure in Type 2 diabetic subjects with complications.³⁸ The UKPDS also could not demonstrate a particular threshold for systolic blood pressure.³⁹

Neither UKPDS nor the HOT Study found a J or U shaped association between systolic blood pressure and complications. There was no indication of a threshold

Table 2 : Diabetic macular edema disease severity scale⁹

Proposed disease severity level	Findings observable on dilated ophthalmoscopy
Diabetic macular edema apparently absent	No apparent retinal thickening or hard exudates in posterior pole
Diabetic macular edema present	Some apparent retinal thickening or hard exudates in posterior pole
If diabetic macular edema is present, it can be categorized as follows	
Proposed disease severity level	Findings observable on dilated ophthalmoscopy*
Diabetic macular edema present	<ul style="list-style-type: none"> ● Mild diabetic macular edema : Some retinal thickening or hard exudates in posterior pole but distant from the centre of the macula ● Moderate diabetic macular edema : retinal thickening or hard exudates approaching the center of the macula but not involving the centre ● Severe diabetic macular edema : Retinal thickening or hard exudates involving the centre of the macula

*Hard exudates are a sign of current or previous macular edema. Diabetic macular edema is defined as retinal thickening and this requires a three dimensional assessment that is best performed by a dilated examination using slit lamp biomicroscopy and/or stereo fundus photography.

below which risk of retinopathy no longer decreased, nor a level above which risk no longer increased. However, in view of various studies which showed that raised blood pressure are associated with increased macro and microvascular events, the American Diabetic Association (ADA) has recommended a blood pressure goal of < 130/80 mmHg.^{39,40}

DO THE BENEFITS DIFFER WITH DIFFERENT AGENTS?

Effects of specific types of antihypertensive agents on diabetic retinopathy have been debated. The EUCLID (EURODIAB Controlled Trial of Lisinopril in Insulin Dependent Diabetes Mellitus) study has studied the effect of ACE inhibitor lisinopril on progression of retinopathy in normotensive people with type 1 diabetes. They observed that lisinopril decreases retinopathy progression in non-hypertensive patients who have Type 1 diabetes with little or no nephropathy, but these findings are to be interpreted with caution as the regression was only by 1 level in the ETDRS grading scale.⁴¹

The hypertension in Diabetes Study (HDS) studied whether tight blood pressure control (< 150/85 mmHg) with either an ACE inhibitor captopril, or a beta blocker atenolol would be able to prevent long term complications of diabetes compared with less tight control group (< 180/105 mmHg). Blood pressure

lowering with captopril or atenolol was equally effective in reducing the onset and progression of diabetic retinopathy. This study provided no evidence that either drug had any specific beneficial or deleterious effect, suggesting that the blood pressure reduction in itself is the important factor than the type of antihypertensives used. In the UKPDS also, it was the overall reduction of blood pressure, which was effective in slowing the progression of diabetic retinopathy, not the type of anti-hypertensive drug used.^{35,42}

A large randomized controlled clinical trial, the DIRECT Study, has just begun with its major objective to examine the efficacy of use of ACE inhibitors to prevent onset and progression of retinopathy in people with Type 1 and Type 2 diabetes mellitus.

CONCLUSIONS

Hyperglycemia along with hypertension increases the risk of micro as well as macrovascular complications of diabetes in Type 2 diabetic subjects. With judicious use of currently available anti-hypertensive agents, it is quite possible to achieve normotensive levels in diabetic subjects. Thus by the control of both of these risk factors, the complication of diabetes can be definitely minimized.

REFERENCES

- Aiello LP, Gardner TW, King GL, et al. Diabetic retinopathy. *Diabetes Care* 1998;21:143-56.
- Rema M, Ponnaiya M, Mohan V. Prevalence of retinopathy in non-insulin dependent diabetes mellitus at a diabetes centre in southern India. *Diab Res Clin Practice* 1996;34:29-36.
- Klein R, Klein BEK, Moss SE, Davis MD, De Mets DL. The Wisconsin Epidemiologic Study of Diabetic Retinopathy II. Prevalence and risk of diabetic retinopathy when age at diagnosis is less than 30 years. *Arch Ophthalmol* 1984;102:520-26.
- Rema M, Shanthirani CS, Deepa R, Mohan V. Prevalence of retinopathy in a selected south Indian population in the Chennai Urban population study (CUPS). *Diab Res Clin Practice* 2000;50(suppl1):1049.
- Kohner EM, Aldington SJ, Stratton IM, et al. United Kingdom Prospective Diabetes Study (UKPDS 30). Diabetic retinopathy at diagnosis of non-insulin dependent diabetes mellitus and associated risk factors. *Arch Ophthalmol* 1998;116:297-303.
- Rema M, Deepa R, Mohan V. Prevalence of retinopathy at diagnosis among Type 2 diabetic patients attending a diabetic centre in South India. *Br J Ophthalmol* 2000;84:1058-60.
- Porta M, Bandello F. Diabetic retinopathy - a clinical update. *Diabetologia* 2002;45:1617-34.
- Fredrick L, Ferris III, Davis MD, Aiello LM. Treatment of diabetic retinopathy. *N Eng J Med* 1999;26:667-78.
- Wilkinson CP, Frederick LF, Klein RE, et al. Proposed international clinical diabetic retinopathy and diabetic macular oedema disease severity scales. *Ophthalmology* 2003;110:1677-82.
- Deepa R, Shanthirani CS, Pradeepa R, Mohan V. Is the "Rule of Halves" in hypertension still valid? - Evidence from the Chennai urban Population Study (CUPS). *J Assoc Phys India* 2003;51:153-57.
- Gillow JT, Gibson JM, Dodson PM. Hypertension and diabetic retinopathy - What is the story? *Br J Ophthalmol* 1999;83:1083-87.
- Klein R, Klein BEK. Blood pressure control and diabetic retinopathy. *Br J Ophthalmol* 2002;86:365-67.
- Klein R, Klein BEK, Moss SE, Cruickshanks KJ. The Wisconsin Epidemiologic study of diabetic retinopathy : XVII : The 14 year incidence and progression of diabetic retinopathy and associated risk factor in Type 1 diabetes. *Ophthalmology* 1998;105:1801-15.
- Kohner EM, Patel V, Rassam SMB. Role of blood flow and impaired auto-regulation in the pathogenesis of diabetic retinopathy. *Diabetes* 1995;44:603-7.
- Grunwald JE, Dupont J, Riva CE. Retinal haemodynamics in patients with early diabetes mellitus. *Br J Ophthalmol* 1996;80:327-31.
- Findi O, Dallinger S, Rami B, et al. Ocular haemodynamics and colour contrast sensitivity in patients with Type 1 diabetes. *Br J Ophthalmol* 2000;84:493-98.
- Rubia GDL, Oliver FJ, Inoguchi T, King GL. Induction of resistance to endothelin-1's biochemical actions by elevated glucose levels in retinal pericytes. *Diabetes* 1992;41:1533-39.
- Tooke JE. Microvascular function in human diabetes. A physiological perspective. *Diabetes* 1995;44:721-26.
- Kastrup J, Norgaard T, Parving HH, Henriksen O, Lassen NA. Impaired autoregulation of blood flow in subcutaneous tissue of long term Type 1 (insulin dependent) diabetic patients with microangiopathy an index of arteriolar dysfunction. *Diabetologia* 1985;28:711-17.
- Fuchsjager Mayrl G, Polak K, Luksch A, et al. Retinal blood flow and systemic blood pressure in healthy young subjects. *Arch Clin Exp Ophthalmol* 2001;239:673-77.
- Jaap AJ, Shore AC, Gartside IB, Gamble J, Tooke JE. Increased microvascular fluid permeability in young Type 1 (insulin dependent) diabetic patients. *Diabetologia* 1993;36:648-52.
- Schlingerman RO, Hinsbergh VWM. Role of vascular permeability factor/vascular endothelial growth factor in eye disease. *Br J Ophthalmol* 1997;81:501-2.
- Way KJ, Katai N, King GL. Protein kinase C and the development of diabetic vascular complications. *Diabetic Medicine* 2001;18:945-59.
- Otani A, Takagi H, Suzuma K, Honda Y. Angiotensin II potentiates vascular endothelial growth factor induced angiogenic activity in retinal microcapillary endothelial cells. *Circ Res* 1998;82:619-28.
- Suzuma I, Hata Y, Clermont A, et al. Cyclic stretch and hypertension induce retinal expression of vascular endothelial growth factor and vascular endothelial growth factor receptor-2, potential mechanisms for exacerbation of diabetic retinopathy by hypertension. *Diabetes* 2001;50:444-54.
- Balasubramanyam M, Rema M, Premanand C. Biochemical and molecular mechanisms of diabetic retinopathy. *Current Science* 2002;83:1506-14.
- The Diabetes Control and Complications Trial Research Group. The effect of intensive treatment of diabetes on the development and progression of long term complications in insulin dependent diabetes mellitus. *N Engl J Med* 1993;329:977-86.
- UK Prospective Diabetes Study (UKPDS) group : Intensive blood glucose control with sulphonylureas or insulin compared with conventional treatment and risk of complications in patients with Type 2 diabetes (UKPDS 33). *Lancet* 1998;352:837-53.
- Stratton IM, Kohner EM, Aldington SJ, et al. UKPDS 50 : Risk factor for incidence and progression of retinopathy in Type 2 diabetes over 6 years from diagnosis. *Diabetologia* 2001;44:156-63.

30. Aiello LP, Cahill MT, Wong JS. Systemic considerations in the management of diabetic retinopathy. *Am J Ophthalmol* 2001;132:760-76.
31. Mathiesen ER, Ronn B, Storm B, Foght H, Deckert T. The natural course of microalbuminuria in insulin dependent diabetes : A 10 year prospective study. *Diab Med* 1995;12:482-87.
32. American Diabetes Association. Detection and management of lipid disorders in diabetes. *Diabetes Care* 1993;16:828-38.
33. Chew EY, Klein ML, Ferris FL, *et al.* Association of elevated serum lipid levels with retinal hard exudates in diabetic retinopathy. Early treatment diabetic retinopathy study (ETDRS) Report 22. *Arch Ophthalmol* 1996;114:1079-84.
34. Sinclair SH, Del Vecchio C, Levin A. Treatment of anaemia in the diabetic patient with retinopathy and kidney disease. *Am J Ophthalmol* 2003;135:740-43.
35. UK Prospective Diabetes Study group : Tight blood pressure control and risk of macrovascular and microvascular complications in Type 2 diabetes. UKPDS 38. *Br Med J* 1998;317:703-13.
36. Estacio RO, Jeffers BW, Gifford N, Schrier RW. Effect of blood pressure control on diabetic microvascular complications in patients with hypertension and type 2 diabetes. *Diabetes Care* 2000;23(suppl2):B54-B64.
37. Schrier RW, Estacio RO, Jeffers B. Appropriate blood pressure control in NIDDM (ABCD) Trial. *Diabetologia* 1996;39:1646-54.
38. Hansson L, Zanchetti A, Carruthers SG. Effects of intensive blood pressure lowering and low dose aspirin in patients with hypertension : principal results of the hypertension optimal treatment (HOT) randomized trial. *The Lancet* 1998;351:1755-62.
39. Adler A, Stratton IM, Neil HAW, *et al.* Association of systolic blood pressure with macrovascular and microvascular complications of type 2 diabetes (UKPDS 36) : Prospective Observational Study. *Br Med J* 2000;321:412-19.
40. American Diabetes Association. Treatment of hypertension in adults with diabetes. *Diabetes Care* 2003;26:S80-S82.
41. Chaturvedi N, Sjolie AK, Stephenson JM, *et al.* Effect of lisinopril on progression of retinopathy in normotensive people with type 1 diabetes. *Lancet* 1998;351:28-31.
42. UK Prospective Diabetes Study Group : Efficacy of atenolol and captopril in reducing risk of macrovascular and microvascular complications in Type 2 diabetes. UKPDS 39. *Br Med J* 1998;317:713-20.

Book Review

ECHO MADE EASY (With Interactive CD ROM)

Atul Luthra

ECHO MADE EASY has been designed to present the intriguing subject of echocardiography in a precise and practical format that is easy to comprehend and ready to assimilate. For the uninitiated reader, the initial chapters are devoted to basic principles of ultrasound and Doppler and to clinical applications of various echo-modalities including 2-D echo, M-mode scan, Doppler echo and colour flow mapping. This is followed by an account of different echo-windows and normal echo-views along with normal values and dimensions. The echo features of various forms of heart disease such as congenital, valvular, coronary and hypertensive disease, are individually discussed. Due emphasis has been laid on pitfalls in diagnosis, differentiation between seemingly similar findings, their causation and their clinical relevance. ECHO MADE EASY is meant for students of cardiology and clinicians keen to integrate this exciting investigative tool into their day-to-day work.

Published by

Jaypee Brothers Medical Publishers (P) Ltd.,
EMCA House, 23/23B, Ansari Road, Daryaganj, New Delhi – 110 002.

Tel: 91-11-23272143/23272703/23282021

Fax: 91-11-23276490/23245683

e-mail: jpmepub@del2.vsnl.net.in

Website: www.jaypeebrothers.com

Indian Price: 295/-